

Automated detection of diabetic retinopathy in digital fundus images

Abhisha Devi C. M¹, Resmi P. L², Pearly Jacob³

¹(ECE, SNGCE Kadayiruppu, India)

²(ECE, SNGCE Kadayiruppu, India)

³(ECE, SNGCE Kadayiruppu, India)

Abstract : Diabetic Retinopathy (DR) is one of the leading causes of blindness in the industrialized world. Early detection is the key in providing effective treatment. However, the current number of trained eye care specialists is inadequate to screen the increasing number of diabetic patients. Early signs of diabetic retinopathy are the presence of microaneurysms, intraretinal hemorrhages, or hard exudates in the retina. In this paper, an automated system for detecting Microaneurysms using a set of optimally adjusted morphological operators in color retinal images is proposed. Afterwards exudates are detected using their high grey level variation, and their contours are determined by means of morphological reconstruction techniques. The algorithm is tested on many images from published database and gives acceptable accuracy.

Keywords - Diabetic Retinopathy; Microaneurysms; Mathematical morphology; Exudates

I. Introduction

The diabetic retinopathy is a complication from diabetes, cause abnormalities in the retina, and in the worst case, irreversible visual loss appears and it is considered one of the most tragic of diabetic complications. Early diagnosis through regular screening and timely treatment has been shown to prevent visual loss and blindness. It is very difficult to cater to this vast set of diabetes patients, primarily because of high costs in reaching out to patients and a scarcity of skilled personnel. Screening offers a cost-effective solution to reach out to patients but is still inadequate due to an insufficient number of experts who serve the diabetes population. Since the eye fundus seems to be sensitive to vascular diseases, fundus imaging is considered as a candidate for non-invasive screening of diabetes. Developments in fundus image analysis have shown promise in addressing the scarcity of skilled personnel for large scale screening.

The diabetic retinopathy typically begins as small changes in the retinal capillaries. The first detectable abnormalities are microaneurysms which are local distensions of the retinal capillary and which cause intraretinal hemorrhage when ruptured[1]. Microaneurysms appear as small dots between the visible retinal vasculature. The disease severity is classified as mild non-proliferative diabetic retinopathy when the first apparent microaneurysms appear in the retina. In time, the retinal edema and hard exudates are followed by the increased permeability of the capillary walls. The hard exudates are lipid formations leaking from these weak blood vessels. This state of the retinopathy is called moderate non-proliferative diabetic retinopathy. As the retinopathy advances, the blood vessels become obstructed which causes microinfarcts in the retina. These microinfarcts are called soft exudates. When a significant number of intraretinal hemorrhages, soft exudates, or intraretinal microvascular abnormalities are encountered, the state of the retinopathy is defined as severe nonproliferative diabetic retinopathy[2]. The severe nonproliferative diabetic retinopathy can quickly turn into proliferative diabetic retinopathy when extensive lack of oxygen causes the development of new fragile vessels. This is called as neovascularisation which is a serious eye sight threatening state. The proliferative diabetic retinopathy may cause sudden loss in visual acuity or even a permanent blindness due to vitreous hemorrhage or tractional detachment of the central retina.

In this project work, microaneurysm detection is implemented using morphological operators in matlab. Afterwards exudates are detected using their high grey level variation, and their contours are determined by means of morphological reconstruction techniques[3]. As the optic disk and exudates have similar attributes in terms of brightness, color and contrast, optic detection is implemented in addition to hard exudates detection[9]. The performance of the algorithm is analyzed by comparing the resulting extractions with ground truth images from DIARETDB1 - Standard Diabetic Retinopathy Database. Suggestions about modification that could be made in DR detection algorithm to improve efficiency are also mentioned.

The paper is organized as follows. Section 2 gives the description of microaneurysm detection. In section 3 hard exudates detection and optic disk detection are discussed. Section 4 analyses the simulation results. Section 5 concludes the work in this paper

II. Detection of Microaneurysms

The proposed system has three main steps. The preprocessing step includes noise removal using median filter. Candidate retinal features which may cause a false detection, i.e., exudates and vessels are detected in the second step. And the last step is microaneurysm detection by using a set of optimally adjusted mathematical morphology. The overall algorithm of microaneurysm detection is shown in Fig. 1.

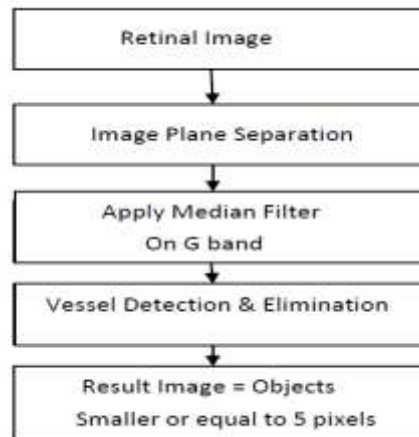


Fig. 1 Algorithm for detection of microaneurysms

2.1 Preprocessing

Retinal images used may have poor contrast, noise and non-uniform illumination. A preprocessing step is needed to improve the image quality prior to the detection step. The green plane (fg) of the original image in RGB plane is used as red lesions such as microaneurysm and blood vessels have the highest contrast with the background in this color plane. A median filtering operation is applied on fg to attenuate the noise.

2.2 Vessel Detection

Vessels are another element in the image that needs to be removed prior the microaneurysms detection since microaneurysms and vessels both appear in a reddish color and microaneurysms cannot occur on vessels. They appear as isolated patterns and disconnected from the vessels. To detect vessels, two intermediate images are generated. The first image is obtained using a closing operator on the median filtered image f_{mf} to eliminate the details and dark patterns (vessels) from the image. A flat disc shaped structuring element with a fixed radius of ten (B1) is used. A second image is obtained by filled in small black dots on the median filtered image f_{mf} with diameters smaller than size of microaneurysm in order to remove small red objects and fill holes in the vessel. The diameter of a microaneurysm lies between 10 and 100 μm , but always smaller than a diameter λ 125 μm . In our image set of size 391 x 300 pixels, the size of a microaneurysm is about 5 pixels. Vessel candidate areas are obtained by the difference between the first image and the second image from the previous step.

$$f_{VesselDiff} = \phi^{(B1)}(f_{mf}) - fill(f_{mf}) \quad (1)$$

where B1 is the morphological structuring element. The candidate vessels are then binarized by thresholding at grey level α_1 as in (2). Let $T = [t_{min}, \dots, t_{max}]$ be an ordered set of grey levels, we have

$$f_{VesselT} = T_{[\alpha_1, t_{max}]} f_{VesselDiff} \quad (2)$$

The objects which have size smaller than 5 pixels are then removed from $f_{VesselT}$.

1.3 Microaneurysm detection

A preprocessed retinal image is used as preliminary image for microaneurysm detection. The extended minima transform is the regional minima of h-minima transform. It is applied to the f_{mf} image. This transformation is a thresholding technique that brings most of the valleys to zero. The h-minima transform suppresses all the minima in the intensity image whose depth is less than or equal to a predefined threshold. The output image f_E is a binary image with the white pixels represent the regional minima in the original image. Regional minima are connected pixels with the same intensity value, whose external boundary pixels all have a

higher value. The output is a binary image. The extended minima transform on the f_{mf} image with threshold value ∞_2 is shown in (3).

$$f_E = EM(f_{mf}, \infty_2) \quad (3)$$

where f_E is the output image. The previous detected vessels are removed from the resulting image as in equation (4)

$$f_{V_{Removed}} = f_E - f_{VesselT} \quad (4)$$

Then the objects with a size smaller or equal to 5 are selected and classified as microaneurysms.

3.. Detection of optic disc

The optic disc is the entrance of the vessels and the optic nerve into the retina. It appears in color fundus images as a bright yellowish or white region. Its shape is more or less circular, interrupted by the outgoing vessels. It is indispensable for our approach to detection of exudates, because the optic disc has similar attributes in terms of brightness, color and contrast. In this work, the contours of optic disc are detected by means of the circular Hough transform. For each edge point, a circle is drawn with that point as origin and radius r . The circular Hough transform also uses an array (3D) with the first two dimensions representing the coordinates of the circle and the third specifying the radii. The values in the accumulator (array) are increased every time a circle is drawn with the desired radii over every edge point. The accumulator, which kept counts of how many circles pass through coordinates of each edge point, proceeds to a vote to find the highest count. The coordinates of the center of the circles in the images are the coordinates with the highest count.

III. Detection of Exudates

Algorithm can be divided into two parts. First, find candidate regions from the luminance channel of the image, these are regions that possibly contain exudates. Then, apply morphological techniques in order to find the exact contours.

3.1 Finding of the Candidate Regions

Regions that contain exudates are characterized by a high contrast and a high grey level. The problem that occurs if we use the local contrast to determine regions that contain exudates, is that bright regions between dark vessels are also characterized by a high local contrast. So, first eliminate the vessels by a closing.

$$e_1 = \phi^{(sB)} f_b \quad (5)$$

with s_1 such that is larger than the maximal width of the vessels on this image, we calculate the local variation for each pixel x within a window centered at x . Let $W(x) \in Df$ be the set of pixels within a window centered at x , N the number of pixels in $W(x) \in Df$ and let $\mu_1(x)$ be the mean value of $I(\zeta) \forall \zeta \in W(x)$, then we calculate e_2

$$e_2(x) = \frac{1}{N-1} \sum_{\zeta \in W(x)} (e_1(\zeta) - \mu_{e_1}(x))^2$$

$$e_3(x) = \delta^{(sB)} (T_{[\alpha_1, f_{max}]}(e_2)) \quad (6)$$

Thresholding the image e_2 at grey level α_1 , we obtain all regions with a standard variation larger than or equal to α_1 , i.e., small bright objects and borders of large bright objects. The threshold α_1 is chosen in a very tolerant manner, i.e., we get the regions containing some exudates, but we also get some false positives. Finally, we have to remove the candidate region that results from the optic disc.

3.2 Finding the contours

In order to find the contours of the exudates and to distinguish them from bright well contrasted regions that are still present in e_3 , we set all the candidate regions to 0 in the original image.

$$e_4(x) = \begin{cases} 0 & \text{if } e_3(x) \neq 0 \\ 1 & \text{if } e_3(x) = 0 \end{cases} \quad (7)$$

and we then calculate the morphological reconstruction by dilation of the resulting image under fg

$$e_5(x) = R_{fg}(e_4) \quad (8)$$

This operator propagates the values $fg(x)$ of pixels next to the candidate regions into the candidate regions by successive geodesic dilation under the mask fg . As exudates are entirely comprised within the candidate region, they are completely removed, whereas regions that are not entirely comprised in the candidate regions are nearly

entirely reconstructed. The final result is obtained by applying a simple threshold operation to the difference between the original image f_g and the reconstructed image e_5 .

$$e_{fin} = f_g - e_5 \tag{9}$$

IV. Results and Discussion

Simulations are done using Matlab. Performance is verified by comparing the results with ground truth image given in DIARETDB1-Standard Diabetic Retinopathy Database.

4.1 Simulation results of microaneurysm detection

A fundus image from DIARETDB1 website is taken as input image for simulation process. Image plane separation is the first step in the proposed algorithm. Fig. 2 represents image in original RGB image, red plane, green plane and blue plane.

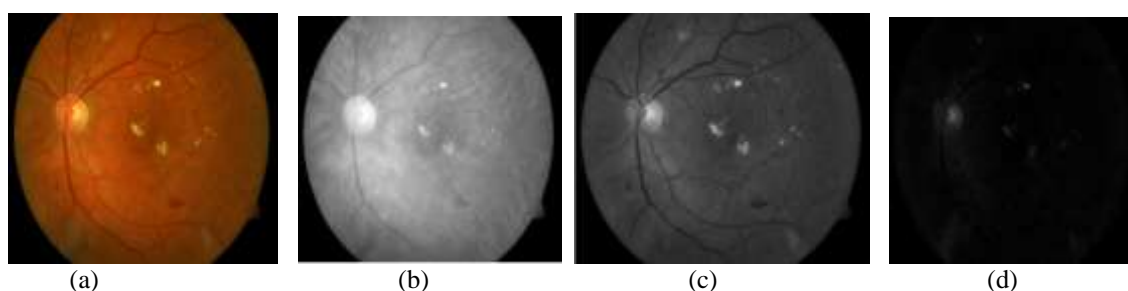


Fig. 2 Retinal images (a) original RGB plane, (b) Red plane, (c) Green plane, (d) blue plane

Fig. 3(a) shows the image after performing closing operation with a disk shaped structuring element on the median filtered image. The difference image of closing image and filled in image is given in fig.3(b). In fig.3(c) extended minima transform is applied on median filtered image. Fig.3(d) represents the detected microaneurysms.

The ground truth image for microaneurysm detection taken from DIARETDB1 website is given in fig.4(a). In ground truth image, the microaneurysms are marked inside the shaded circles. The analysis of simulation result is done by checking whether the microaneurysms detected from matlab program lies inside the shaded circles in ground truth image. The shaded circles are extracted from the ground truth image and the addition of result image of matlab program and the image containing the shaded circles are performed. The result shows that most of the microaneurysms are within the shaded circle (fig. 4(b)).

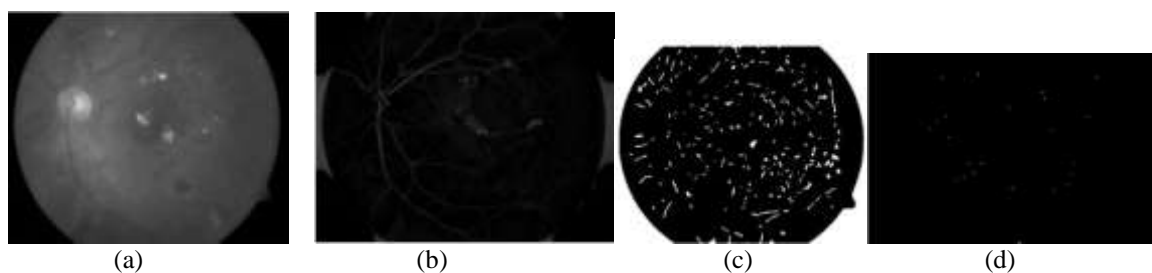


Fig. 3. Microaneurysm detection (a) image after closing, (b) Difference image, (c) Extended minima transform image, (d) Detected microaneurysms




Fig.4 (a) Ground truth image, (b) Analysis of microaneurysm detection

4.2 Simulation Results of exudate detection

Luminance channel of the retinal image is used as the preliminary image for hard exudate detection. The image plane separation of input image is done and luminance channel(fig.5(a)) is obtained from the three channels using equation (10). Afterwards closing is performed with disk shaped structuring element on luminance channel which is shown in fig.5(b).

$$I=0.299*R+0.587*G+0.114*B \tag{10}$$

Local standard deviation of each pixel is calculated on the image obtained after performing closing operation. Then the image is converted into binary with a threshold value α_1 (fig. 5(c)).The non zero regions in this image is called candidate region, where there is high possibility for the presence of hard exudates. These candidate regions are set to zero in luminance channel which is shown in fig. 5(d). Morphological reconstruction by dilation is performed on fig. 5(d) and then the difference between luminance channel and morphologically reconstructed image is calculated which is shown in fig. 5(f). Optic disk and hard exudates are present in fig.5(f), so we need to remove the optic disk. Fig.6 shows optic disk detection using Hough transform and final result is shown in fig. 7(The green circle represents the optic disk).




Fig. 5 (a) Luminance channel of retinal image, (b) Closing of luminance channel, (c) Local standard variation in sliding window, (d) Candidate regions set to zero in the original image, (f) Difference image

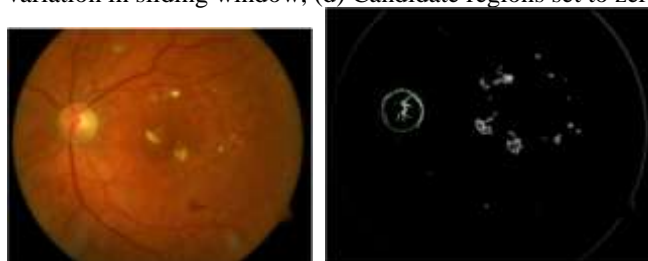


Fig. 6 Optic disc detection Fig. 7 Detected exudates

V. Conclusion and future works

In this paper, a detection algorithm is analysed for candidate Microaneurysms and Hard exudates in color fundus images with the goal of providing a suitable tool for diabetic retinopathy screening. Microaneurysm detection can be considered as early detection of Diabetic Retinopathy and the detected exudates can be used to identify the severity of the retinal decay. The analysis of simulation results with ground truth images from DIARETDB1 - Standard Diabetic Retinopathy Database shows that the algorithm works with acceptable accuracy. Further improvements can be done in this work by implementing a classifier which takes retinal image as input and classify the image as diseased or not.

References

- [1] Akara Sopharak, Bunyarit Uyyanonvara and Sarah Barman, (2011). " Automatic Microaneurys Detection from Non-dilated Diabetic Retinopathy Retina Images Usin Mathematical Morphology Methods. ", *IAENG International Journal of Computer*, Vol.7 pp.405-431.
- [2] Akara Sopharak, Bunyarit Uyyanonvara, Sarah Barman, Sakchai and NattapolWongkamchang,(2010). " Fine Exudate Detection using Morphological Reconstruction Enhancement. ", *International Journal Of Applied Biomedical Engineering*, VOL.1,NO.1, pp. 45-50.
- [3] Ardimas Andi Purwita, Kresno Adityowibowo, Ashlih Dameitry, Made Widhi Surya Atman, (2011). " Automated Microaneurysm Detection Using Mathematical Morphology.", *International Conference on Instrumentation, Communication, Information Technology and Biomedical Engineering Bandung, Indonesia*
- [4] Conor Heneghana , John Flynn, Michael OKeefec, Mark Cahille, (2002). " Characterization of changes in blood vessel width and tortuosity in retinopathy of prematurity using image analysis. ", *Medical Image Analysis*, Vol.6, pp. 407429.
- [5] Kenneth W. Tobin, V. Priya Govindasamy, Thomas P. Karnowski, (2007). " Detection of Anatomic Structures in Human Retinal Imagery. ", *IEEE Transactions On Medical Imaging*, VOL. 26, NO. 12, pp. 1729-1739.
- [6] K.NARASIMHAN, NEHA.V.C, K.VJAYAREKHA, (2012). " A Review Of Automated Diabetic Retinopathy Diagonosis From Fundus Image. ", *IJournal of Theoretical and Applied Information Technology*, Vol. 39 No.2, pp. 225-238.
- [7] Neera Singh, Ramesh Chandra Tripathi, (2010). " Automated Early Detection of Diabetic Retinopathy Using Image Analysis Techniques. ", *International Journal of Computer Applications*, pp. 18-23
- [8] Niall Pattona, Tariq M. Aslanc, Thomas MacGillivrayd, Ian J. Dearye, Baljean Dhillonb, Robert H. Eikelboomf, Kanagasingam Yogesana, Ian J. Constablea, (2006). " Retinal image analysis: Concepts,applications and potential. ", *Progress in Retinal and Eye Research*, pp. 99127